

## **The Peculiarities Of The Spinal Column Joints At Muskrat (*Ondatra Zibthica*)**

**Mihaela SPĂTARU, Constantin SPĂTARU, Vasile VULPE**

Faculty of Veterinary Medicine from Iasi,

[mspatarufmv@yahoo.com](mailto:mspatarufmv@yahoo.com)

**Abstract.** The mobility of the muskrat head is determined by the massive cervical muscles and the particularity of the joints and the bones structures. Considering the dorso-ventral flattening of the cervical vertebrae C3-C7, the long transverse processes, the presence of joints between the transverse processes of the vertebrae C5-C6, C6-C7, the jointing surface like a "Z" between the jointing processes of cervical vertebra and that the first ribs is jointed with the transverse process of C7 vertebra may show that the cervical vertebrae produce a complex rigid, the neck movements are products only of the occipito-atlanto-axial jointing complex. At muskrat, each of two occipital condyles consists of two subunits separated by an articular notch: a classic biconvex condyl lateral placed, and a capitulum, ventro-medially. During the head flexion, the angle between the head and cervical region is about 90°, and is condyl occipital is articulated with the atlas through the capitulum (subunits of the occipital condyle) so that movement possible is flexion, extension, and especially for side widening area visual and audible. Conformation of the bones and articular structures of the lumbar region of the muskrat shows increased mobility, the flexion and the extension is mainly due to large areas of joint of the jointing process joints. The region of the tail is highly mobile, being used for body direction during the swimming.

**Key words:** muskrat, neck, head, occipital, bone, joint

### **INTRODUCTION**

Environment life its essential fingerprint and the locomotor system of animals with a permanent shape bone structure, joints and muscles in the fight for survival. Muskrat is a medium-sized rodent that it moves with equal ease on land or swimming, with characters of the osteo-ligamentar common rodents of the same living conditions and character of particular species adapt to living conditions.

### **MATERIALS AND METHODS**

To study the spinal column joints were used for three muskrat shot from fish ponds in the county of Iasi. Were conducted the stratified dissection studies are muscles, areas of insertion marrow and joints of the spine muscles. After these, were prepared through dissection the joints, showing the extension the jointing surface, the type of the joint and the movements possible. Following the pieces dissect were made the photos and the drawings. Research results were correlated with the same obtained from literature and being interpreted by the principle of comparative anatomic form-based, cause-effect.

## RESULTS AND DISCUSSIONS

In all species of mammals, the occipito-atlantis articulation between the occipital condyles and glenoid cavities of the atlas, realizing the one for each jointing condyle.

At muskrat, each condyl of the occipital is composed by two sub-units joints: a portion of back side that appears as a classical biconvex condyl joint, and a ventro-medial portion, with the jointing surface like a small articular head. The condylar subunits are separated by an incomplete notch that is deep (4). This organization determines the occipital condyles segmentation and the glenoid cavities of the atlas, the same, in a dorsal cavity, and the largest one lying ventral cavity, smaller ones being separated by an apparent notch (Fig. 1).

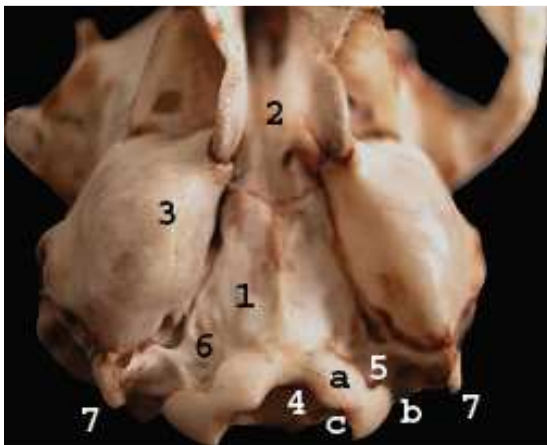


Fig. 1. The occipital bone at muskrat, ventral view

1- os occipitale, pars basilaris, 2- os basisphenoidale, 3- bulla tympanica, 4- foramen magnum, 5- condylus occipitalis: a- pars ventromedialis (capitulum), b- pars lateralis (condylus), c- incisura, 6- fossa paracondilara, 7- processus paracondilaris

Fig. 1.

The articular capsule is common, but each condyl make a joint with sinovial own. The articular capsule is large dusk on the circumference surface joints, capsular ligament is thick both dorsal and ventral, which is the insert between the cranial notch of the atlas and the caudal occipital incisure, weaving with the apical ligament of the dental process of the axis and the tectoria blade (Fig. 2, 3). The dental process is articulates with the occipital through three ligaments: two lateral alaris ligaments, inserted on lateral edge of the dental process and the ventral occipital circumference of the foramen magnum and one median placed, the ligamentum apicis dentis, inserted in the bottom of the ventral occipital notch. The dental process is maintained through the fovea dentis transverse ligament of the atlas (lig. transversarium atlantis) insert between the notches of the circumference of the glenoid cavities (Fig. 4).

Joint mobility of the occipito-atlanto-axial complex at muskrat is the simultaneous operation while successive parts that compose the joints. During swimming, muskrat head is placed above the surface water between the head and neck form an angle of  $90^{\circ}$ . Broadening the scope for visual and audible, muskrat keep his head high, with the cervical region, the head is facing forward, flex the atlas. At this point, the ventral glenoid cavity of the atlas is articulated with the ventral subunits of the occipital condyl (looking as the jointing head) and the dental process of axis arrives till the edge of the ventral notch of the occipital. Thus, the flexion and extensions are possible and easy lateral sliding movement (rotation), acquired a joint biaxial. In this position, the apical ligament of the dental process creates, by pressure enforced on the atlas, an ovoid area, smooth, covered by cartilage, located on the ventral arc, between glenoid cavities.

The dorsal jointing capsule is strong, being composed by fibers fan arranged between the atlas tuber and circumference occipital hole. The other fibers appear to enforce the

capsule, dorso-lateral located, oriented between the atlas and the notch of each occipital condyl.

Ventrally, the articular capsule is lower in fiber compared to the back side, connecting the cranial articular circumference of atlas with the insertion ligament ridge of the basioccipital (Fig 2).

The articular capsule side presents draft on the approach to the tympani bubbles up on wings of atlas (Fig.3).

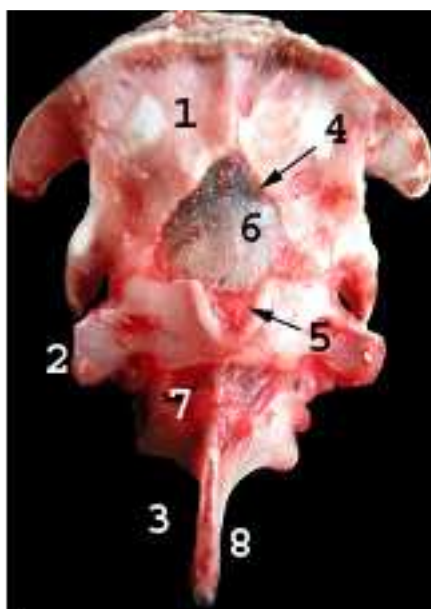


Fig. 2

Fig. 2. The dorsal view of the occipito-atlo-axialis jointing complex at muskrat

1- os occipital, 2- atlas, 3- axis, 4- incisura foramen magnum, 5- incisura dorsalis atlantis, 6- capsula articularis dorsalis articulationis occipito-atlantis, 7- capsula articularis dorsalis articulationis axo-atlantis, 8- processus spinosus axis.

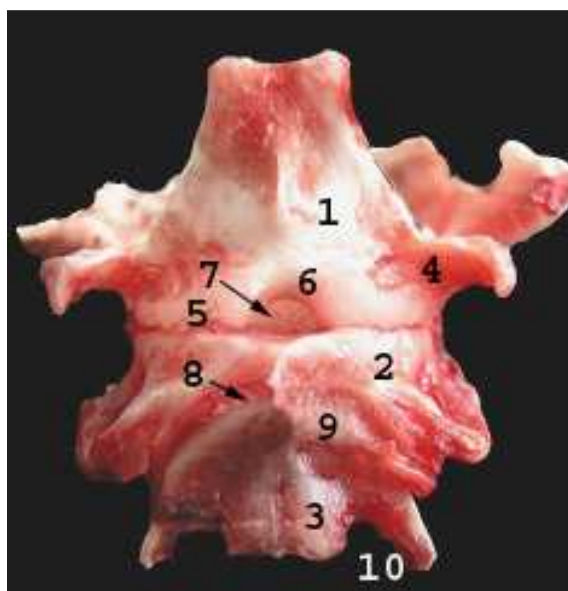


Fig. 3.

Fig. 3. The ventral view of the occipito-atlo-axialis jointing complex at muskrat

1- os occipitale, pars basilaris, 2- atlas, 3- axis, 4- processus paracondylaris, 5- condylus occipitalis, 6- incisura ventralis occipitalis, 7- capsula articularis ventralis articulationis atlanto-occipitalis, 8- capsula articularis ventralis articulationis atlantoaxialis, 9- facies articularis axialis lateralis, 10- processus transversus axialis.

When the muskrat adopts the hydrodynamic body position, is produced the extension of the occipito-atlo-axoidal joint. The ventral arch of the atlas is protected to the pressure produced by the dental process, through glenoidal thickness satisfying both this role and separates cavities joints (sinovial occipito – atlantal joint by the atlo – axoidal joint). The extension of the atlo-axoidal joint is possible because the interarch space is large, the movement being limited by the cranial edge of the dental process.

The extension is favored by the jointing surfaces of caudal faces of the atlas and the same cranial of the axis, triangular and plan in shaped for the atlas and easily plan - convex on prolonging laterally on the axis.

The bodies of the cervical vertebrae C2-C7 are articulated by an intervertebral disk that is thin and very well engage to the periphery of the vertebra body. The cranial and caudal jointing areas are flat type and oval, transverse diameter is two times higher than the back - ventral.

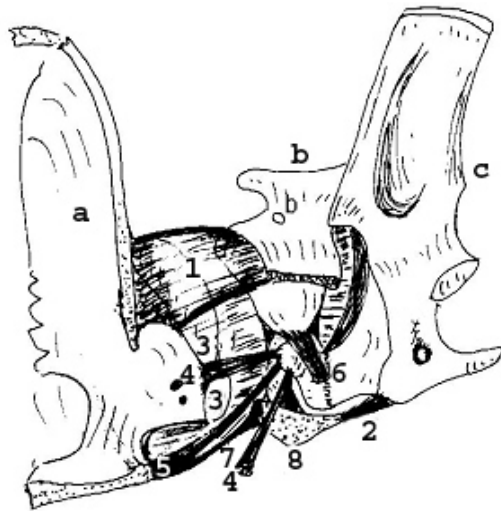


Fig. 4. Occipito-atlo-axoidien joints in muskrat

a- os occipitale, b- atlantis, c- axis, 1- capsula articularis atlantooccipitalis, 2- capsula art. atlantoaxialis ventralis, 3, 3'- condylus occipitalis, 4- lig. alaria, 5- lig. apicis dentum, 6- lig. transversum atlantis, 7- lig. capsularis ventralis atlantooccipitalis, 8- arcus ventralis atlantis.

Fig. 4.

Articular surface is slightly wavy, the cranial face is concave back ventral and lateral, close to the transverse processes presents a jointing prominence surface so that the joints take part in a slightly concave transversely. Caudal jointing surface has a wavy, concave-convex back - slightly convex and ventral to the transverse. The intervertebral disc is low, sprawling all over joints, more thick and thin peripheral central.

The jointing processes are lateral displaced, slightly above the edge of the caudal vertebrae arch defining very narrow intervertebral spaces. The surfaces of joints are plane joints processes. The surfaces of the cranial articular processes are oriented back-medial, the same caudales have the jointing faces latero – ventral orientated. Means of strengthening the joints are represented by an articular capsule ligament which is very short allowing only slight lateral sliding (Fig. 6).

Looking the back flattening of the ventral cervical vertebrae (transverse diameter is twice as wide than sagittal) progressive elongation of the transverse processes from the third to the seventh cervical vertebra, observed that the dorsal cervical region takes issue with trapezoidal small base of about 1.5 cm and the large 2 cm. Also, the top of the transverse processes are very close between them, achieving the intertransversary joints C5 - C6, C6 - C7 (Fig.5, 6).

Deployment to the lateral jointing processes (a result of shortening and vertebrae enlarging), elongation of the transverse surface joints of the vertebrae bodies, deployment side of the transverse processes and back - ventral flattening of the vertebral body shows that the movements of the neck made of cervical vertebrae C3 - C7 are limited to moving the flexion and extension to the side. The rotation are almost impossible to achieve, they performed only at the occipito-atlo-axoidal jointing complex. Thus, the cervical vertebrae C3 - C7 carried out a complex rigid maintaining cervico-thoracic curvature increased.

The jointing ligaments are represented by the upper vertebral ligament, situated on the dorsal vertebrae bodies that are used for inserts intermediate acting, powerful muscles in the head movements, occipito-atlo-axoidien joint taking all the movements that the cervical

region can achieve. Ligament is a quadrilateral, is very wide because the enlarging of the body of the vertebrae. Cranially is inserted on the dental process, and caudally, to the extremity reaches the sacrum also passing over each intervertebrae disc.

The spinous processes from the axis till the fifth cervical vertebra are visible because to the sixth and seventh vertebrae is reduced to a dorsal tubercle. The interspinosus ligament is elastic, in the cervical region is visible just above, have a fan with the tip of the spinous processes of the first cervical vertebra and into the skull, until the caudal spinous process of axis.

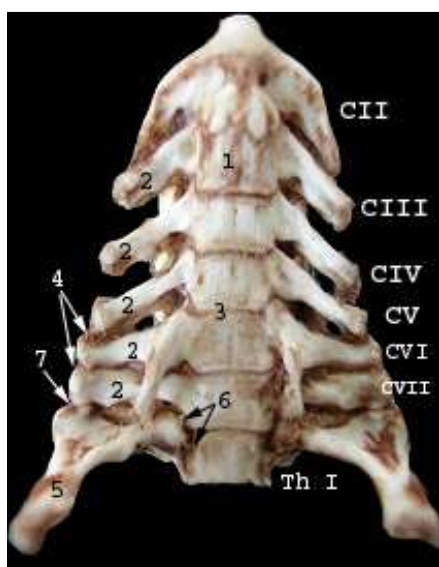


Fig. 5.

Fig. 5. The ventral aspect of the intervertebral cervical joints at muskrat

CII-CVII- vertebrae cervicales, Th I- vertebra thoracica I, 1- corpus vertebrae, 2- processus transversus, 3- discus intervertebralis, 4- articulationes intertransversariae cervicales, 5- costa I, 6- articulatio capitis costae, 7- articulatio costotransversaria vertebra cervicale VII

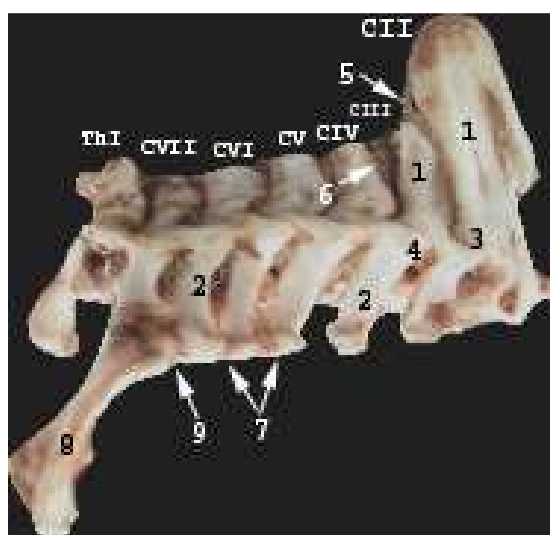


Fig. 6.

Fig. 6. The intervertebral cervical joints in muskrat, the joints between articulationes process

CII-CVII- vertebrae cervicales, Th I- vertebra thoracica, 1- processus spinosus, 2- processus transversus, 3- processus articularis cranialis, 4- processus articularis caudalis, 5- lig. nuchae, 6- ligg. intrtransversalia, 7- articulationes intertransversariae cervicales, 8- costa I, 9- articulatio costotransversaria vertebra cervicale VII

The cervical ligament appears as a small fascicle median being used more as a muscle insertion than balanced by the counterpoise of the head (Fig.6). Detach from the tip of spinous process thoracic T3-T4, cranially oriented and where is little thick and insert the tip of the spinous process of axis and the external occipital protuberance (1).

Cervical ligaments are essential role in maintaining the cervico –thoracic curvature that at muskrat is very marked, highlighting the position of neck extension region. The joint between the head of the ribs with the thoracic vertebrae is achieved through a joint synovial type in which the two convex surfaces that are congruent being separated by a small tubercle or a tuft for ligament insertion.

The caudal fovea, on the anterior vertebra placed, has a surface larger than cranially, it increases in size to the rib of the tenth (last bedding) and then at the last thoracic vertebra to be reduced to extinction. The articular capsule is short, the capsular ligament, ventrally, has a strong radiary ligament developed what is beam dusk on intervertebral disc whose fibers are waved with the vertebral ligament and ventral beam that insert on the homonym vertebrae. This beam is placed between the head, neck and tubers of the each rib, intersected with the capsular ligaments of the costo-transvrsary joint. This ligament is very strong and is enriched with elastic fibers (2).

A particularity of the rib-vertebral joint at muskrat is no conjugate ligament (between the two symmetrical ribs) the ligament of the head rib dusk on a ridge that separates the two surfaces of the head joints rib (3, 5). Fibers converge into a ligament that is partially inserted with yellow ligaments on the circumference of vertebral lateral hole, the intervertebrae disc and the rest into the fibers of the dorsal longitudinal ligament.

Articulates the lumbar vertebrae between them, the discs between them being much thicker compared to those of cervical and thoracic region, are concave on both sides, and hosting a small nucleus with pulp evenly distribute pressure forces (Fig. 7).

Areas of jointing body lumbar vertebrae are the amficirțian type (easily plan - convex) which allows greater mobility of this region.

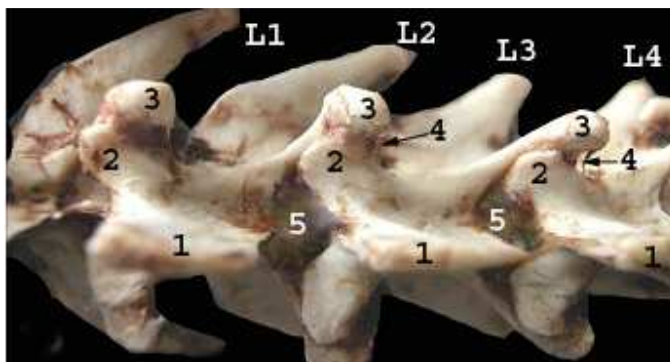


Fig. 7. The dorsal aspect of the lumbar intervertebral joints

L1- L4- vertebrae lumbar I-IV,  
1- processus spinosus, 2- processus  
articularis cranialis, 3- processus  
articularis caudalis, 4- articular  
processum articularium.

Fig. 7.

The cranial jointing surfaces of the cranial process are concave and very large, from the top face of the mammary processes to the arch of vertebra and the spinosus process. Areas of joint of the caudal processes are easily plan-convex. The means of connection are represented by a large articular capsule, inserted in the circumference of joint surfaces.

The cranial and caudal surfaces of the articular processus are superimposed on "X" over one another. Thus, the movement in flexion and extension of the lumbar region is broad, during the flexion the caudal jointing processes go to the anterior limit of the surface of the cranial jointing processes like the arms of a scissors. In extension, the caudal jointing processes exceed the posterior limit of the cranial jointing processes (Fig. 7).

Side movements are exacerbated by the appearance amficirțian of the vertebral body, intervertebral disc thick, wide spaces interarcuale and by the jointing surface of the articular processes are joint surfaces at the same level with joints that are formed between vertebrae bodies.

Spinous processes are late, almost as long as the vertebrae are articulated together by interspinos broad ligament, with the lamellar aspect. At the top is forming a strong ligament insertion on the free extremity, with triangular aspect of each lumbar vertebra.



Interarcual spaces are wide, as well as vertebral lateral holes, most visible at the last three lumbar vertebrae, so that side movements, the extension and flexion are stronger in the mid-posterior lumbar region.

The first three dorsal vertebrae of the tail completed the basin. They have a long body, and have articular processes developed. Body coccigian vertebrae have the articulation surfaces of amficerțian and the first two, three vertebrae are articulated through the jointing processes, too. Mobility of the tail increases towards caudal, in the same time with the reduction processes that are detached from the body.

## CONCLUSIONS

1. The head flexion during swimming, the head is high above the water, achieving cervical region with an angle about  $90^0$ . Thus, the apical ligament of the dental process polishes an ovoid and smooth surface, lying between the two glenoid cavities of the atlas.

2. In the extension of the head (during adopting hydrodynamic body position) the ventral arc of the atlas is protected by a pressure that is produces by the dental process through a thick fibro-cartilage structure.

3. Cervical vertebrae C-3 - C-7 carried a rigid complex that allows limited the movement, flexion and extension to the side movements are almost impossible to make them being made only in occipito-atlanto-axial jointing complex.

4. The cervical vertebra C-7 presents a jointing surface on the transvers process placed for articulate with the first rib.

5. The ligament of the head of the rib is inserts between the crest that separates the two surfaces of the head of the rib and the circumference of the hole vertebral lateral, intervertebral disc and dorsal longitudinal ligament.

6. The jointing processes of the lumbar vertebrae are superimposed on "X" over one another, facilitating the movement of large flexion and extension.

7. The interarcuale spaces are wide, as well as vertebral lateral holes, most obvious in the last three lumbar vertebrae, so that side movements, the extension is flexion are stronger in the mid-posterior lumbar region.

## REFERENCES

1. Coțofan, V., Hrițcu Valentina – Caractere morfologice diferențiale ale scheletului axial la nutrie comparativ cu unele mamifere domestice. Seminar Șt. I.A. Iași, 1982, p. 62-63.
2. Coțofan, V., Cura, P., Hrițcu Valentina – Sistemul osteo-ligamentar occipito-axo-atloidian la dihorul de crescătorie. Simp. Șt. I.A. Iași, 1987, p. 34.
3. Coțofan, V., Spătaru, C., Spătaru Mihaela – Particularități morfofuncționale ale cavității toracice la nutrie. Lucr. Șt. La al VIII-lea Congres Național de Med. Vet., Băile Felix, 2000, p. 27.
4. Spataru Mihaela- Diferențele anatomice dintre craniile de bizam tanar si adult, Lucr. Stiint la Simp. Stiint de Med. Vet., Iași, 2005, p.273
5. Spătaru Mihaela, Coțofan V., Spătaru C- Peculiarities of Thorax Intervertebral Joints in muskrat (*Ondatra zibethica*)- revista „Cercetari Agronomice in Moldova”, vol I, (129), ISSN 0379-5837, 2007- p. 53-58.