

# Radiological Investigations of Head Pathology in Dogs

Glad MORAR<sup>1\*</sup>, Radu LACATUS<sup>1</sup>, Robert Cristian PURDOIU<sup>1</sup>, Ionel PAPUC<sup>1</sup>

<sup>1</sup>Faculty of Veterinary Medicine, Department of Semiology, University of Agricultural Sciences and Veterinary Medicine, Cluj-Napoca, 3-5, Mănăştur Street, 400372, Romania

\*Corresponding author e-mail: [glad.morar@gmail.com](mailto:glad.morar@gmail.com)

Bulletin UASVM Veterinary Medicine 71(2) / 2014,

Print ISSN 1843-5270; Electronic ISSN 1843-5378

DOI:10.15835/buasvmcn-vm: 10855

---

## Abstract

Skull radiography is usually indicated for investigation of clinical signs interesting different parts of the head such as trauma, pain, jaw problems, dysphagia, deformity of the sinuses, ear disease and signs of nasal and dental disease. The aim of the study was to identify the most relevant radiographic methods and techniques in dogs, capable of providing accurate information for a correct diagnosis regarding the head pathology and showing the importance of radiological investigations in different head injuries. The study was conducted during the period of 2012 – 2014 in the Roentgen Diagnosis Laboratory of the Faculty of Veterinary Medicine of Cluj-Napoca and in a private clinic from Cluj-Napoca, considering a total number of 100 clinical which 21 cases needed radiological examination. The Roentgen machines used for taking the radiographies were a TEMCO – GR – X® model and a Poskom model PXP-40HF® using Agfa and Kodak films and an automatic developing machine HU.Q HQ – 350XT®. The animals were sedated and the positioning was adjusted according to the area of interest. The working parameters of the Roentgen machines were set according to the size and density of the interested area.

From the 21 cases selected after the clinical exam, we found 3 sinusal disease, 2 zygomatic fractures, 1 maxillary fracture, 2 tympanic bullae affections, 3 cranium fractures, 3 nasal bone diseases, 3 dental affections and we also found 4 foreign bodies in the soft tissues of the cranium. In this study, we have shown the importance of radiological exam regarding head pathology showing simple and fast methods of diagnosing different affections and the limitations of the radiological exam.

**Keywords:** *skull, head trauma, radiography, dog.*

---

## INTRODUCTION:

Modern medicine starts from the presumption of an early and exact diagnostics. There is no pathological affection in which the imagistic evaluation cannot bring contribution to the final diagnostic. Using modern investigation methods doesn't exclude the importance of the initial clinical examination, they complete the clinical examination. The physician, regarding the clinical findings will guide the imagistic evaluation.

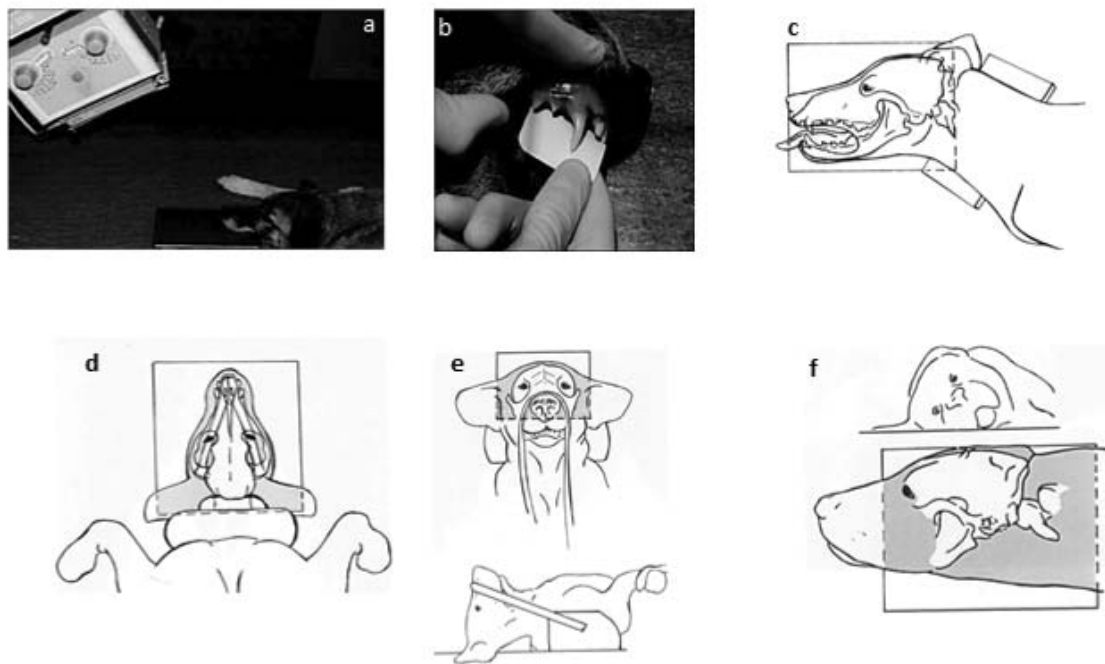
Indications for skull radiography are mainly for investigation of clinical signs relating to different parts of the head, but in some cases systemic metabolic disease affecting bone can be seen in the skull (Thrall, 2012). Typical clinical signs include deformity, swelling or discharging

sinus, trauma to the head area, ear disease, proptosis, pain in the head area, problems with jaw movement, including open-mouth jaw locking, suspected metabolic disease that may involve the skull, signs referable to nasal disease, signs referable to dental disease (Ruth, 2006).

The aim of the current study was to explore different methods for highlighting some particularities in dog skull trauma, to study the radiological technique for different skull pathology and to make a correlation between clinical and radiological findings.

## MATERIALS AND METHODS:

The study was conducted during the period of 2012 – 2014 in the Roentgen Diagnosis Laboratory



**Fig. 1.** Bisect angle technique (a); parallel technique (b); lateral position (c); dorso-ventral position (d); rostrocaudal position (e); lateral-oblique position (f).

of the Faculty of Veterinary Medicine of Cluj-Napoca and in a private clinic in Cluj-Napoca on a number of 100 clinical exams from which 21 cases needed radiological examination. The biological material used for the study consists in 100 dogs of ages between 2 months and 12 years old from breeds including Labrador Retrievers, Rottweiler, Golden Retrievers, German Shepherds, Cocker Spaniels and cross breeds with different head pathology including sinusal disease, zygomatic fractures, maxillary fracture, tympanic bulla affections, cranium fractures, nasal bone diseases, dental affections and foreign bodies.

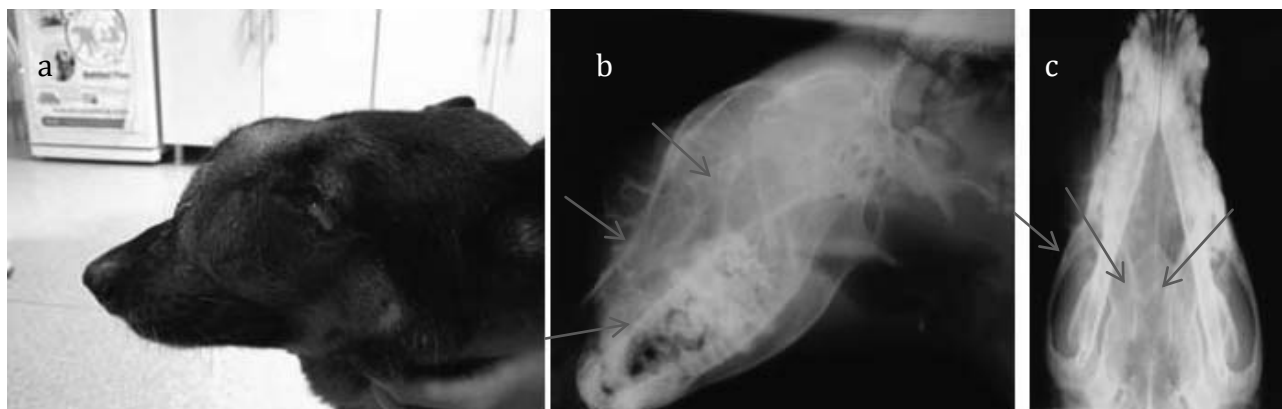
The Roentgen machines used for taking the radiographies were a TEMCO – GR – X model and a Poskom model PXP-40HF using Agfa and Kodak films and an automatic developing machine HU.Q HQ – 350XT. The working parameters of the Roentgen machines were established according to the size and density of the interested area. We used values from 0.6mA/58kV to 2mA/68kV at 100cm distance from the X-ray generator for the patient examined using the Poskom machine and 15mA/55kV to 20mA/66kV at 100cm distance from the X-ray generator for the patient examined using the TEMCO machine.

The animals were sedated using a combination of ketamine and diazepam in dose of 5 mg/kg of ketamine and 0.25 mg/kg diazepam administered i.v. through an intravenous catheter (Kastner, 2007).

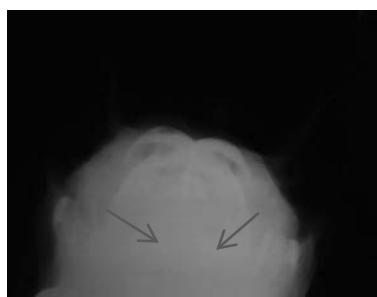
The positioning was adjusted according to the area of interest. For the teeth radiographies the bisect angle technique and parallel technique were used (Lăcătuș *et al.*, 2010) and for the other head trauma we used lateral position, dorso-ventral position, rostrocaudal position and lateral-oblique position (Lisa, 2007) (Fig.1 a, b, c, d, e, f).

## RESULTS AND DISCUSSIONS

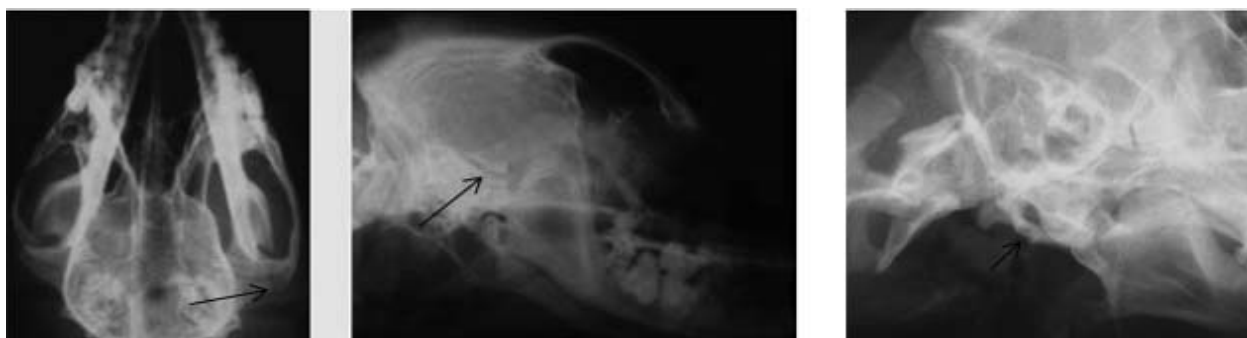**Sinusal and nasal bone diseases.** Usual clinical findings in sinusal diseases consisted in excessive sneezing, nasal discharge (nasal sinuses), pain and swollen of the frontal region with dense fluid secretion in the eye region (Fig.2a). Radiological findings included areas of radiopacity of the frontal or nasal sinuses, we have use the lateral (Fig. 2b), dorso-ventral (nasal sinuses) (Fig. 2c) and rostrocaudal positions (frontal sinuses) (Fig. 3). For the nasal bone it can be used the lateral and dorso-ventral positioning (Fig 2b, 2c) and intraoral bisect angle technique. For the



**Fig. 2.** 10 years old German Sheppard with frontal and nasal sinusal problems, white fluid coming out from the internal eye angle (a); lateral aspect of the nasal and frontal sinuses, high radiopacity in the nasal and frontal sinus region with periosteal reaction of the nasal bone (b); dorso-ventral view of the skull, increased radiopacity of the left nasal sinus and half of the right nasal sinus and periosteal proliferation of the left nasal bone (c).

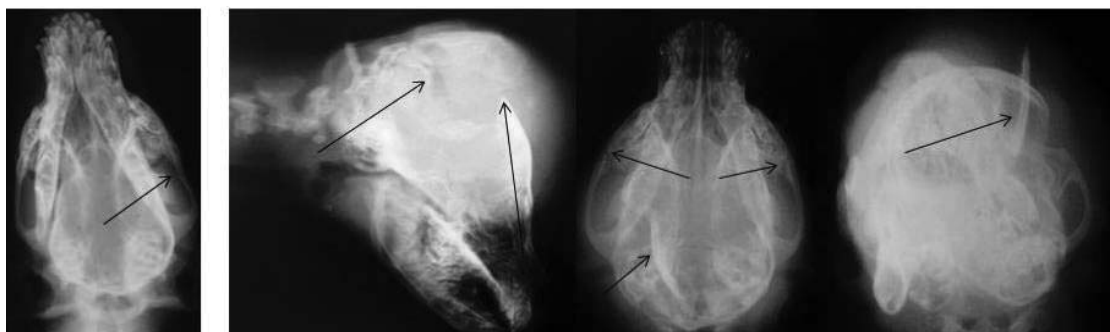

**Fig. 3.** Rostrocaudal view of the skull, increased radiopacity in both frontal sinuses.



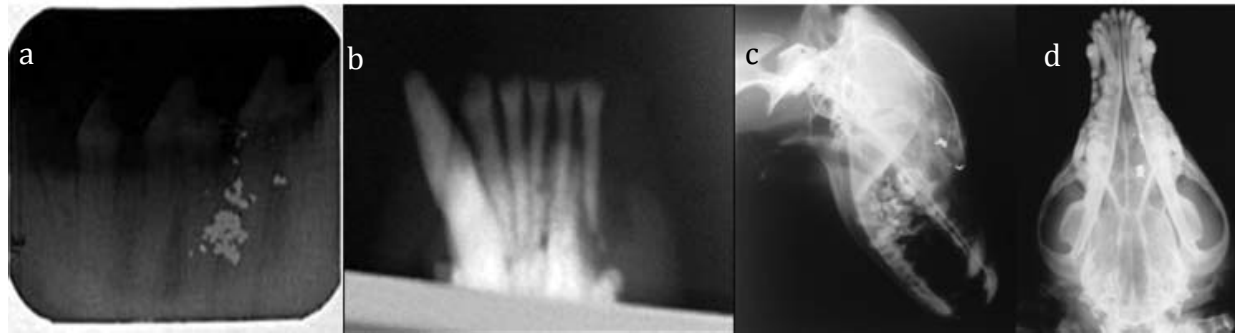
**Fig. 4.** 10 years old Cocker Spaniel with zygomatic fracture dorso-ventral view (A) and lateral view of the skull (B).

**Fig. 5.** Lateral oblique view of the skull, thickened aspect of the tympanic bulla;



**Fig. 6.** 4 month old crossed breed dog, dorso-ventral view of the skull with a caudal maxilla fracture.

**Fig. 7.** 2 month old crossed breed dog, lateral skull view of a frontal bone fracture (a), dorso-ventral view of left and right maxillary fracture and frontal bone fracture with medial displacement (b) and rostrocaudal view of the fractured frontal bone (c);



**Fig. 8.** Intraoral parallel technique, radiopaque foreign bodies of unknown origins in the molar region (a); bisect angle technique, missing lower jaw canine (b); lateral view of the skull with radiopaque foreign bodies (c); dorso-ventral view of a skull with radiopaque foreign body (d);

**Tab. 1.** Working parameters for the TEMCO and the Poskom X-ray machines for different dog sizes and regions, the positions which require anesthesia and the best techniques for the encountered pathology.

Dog positioning	Identified lesion	Dog size	TEMCO		Poskom		Sedation
			kV	mA	kV	mA	
Bisect angle technique	Dental and upper jaw	Small	55	15	58	0.6	Yes
		Medium	60	15	60	0.8	Yes
		Large	66	15	62	1	Yes
Parallel technique	Dental	Small	55	15	58	0.6	Yes
		Medium	60	15	60	0.8	Yes
		Large	66	15	62	1	Yes
Lateral position	Cranium fractures, nasal bone diseases, foreign bodies, nasal sinuses	Small	58	15	58	0.6	No
		Medium	62	18	62	1.3	No
		Large	66	20	68	2	No
Dorso-ventral position	Cranium fractures, nasal bone diseases, nasal sinuses, foreign bodies	Small	56	15	58	0.8	No
		Medium	60	16	64	1.3	No
		Large	64	18	68	1.8	No
Rostro caudal position	Sinusal disease, cranium fractures	Small	55	15	58	0.6	Yes
		Medium	58	16	60	1.3	Yes
		Large	64	17	64	1.8	Yes
Lateral oblique position	Tympanic bulla affections	Small	58	15	58	0.6	Yes

frontal sinuses we recommend the rostrocaudal position (Fig. 3).

**Zygomatic fractures.** Clinical findings included pain in the traumatized area and bone crepitation. Also, soft tissue wounds were found. Two exposures were necessary, lateral (Fig. 4a)

and dorso-ventral (Fig. 4b), the fracture line was usually visible in both positions.

**Tympanic bulla.** Clinical signs of tympanic bulla pathology included chronic otitis, tilted head, foreign bodies, pain in the ear region. Radiologically was diagnosed using the lateral oblique position on

sides, left and right, for comparison. Radiological findings included thickening, thinning or integrity changes of the tympanic bulla (Fig. 5).

#### **Maxillary fractures and cranium fractures.**

Fractures of the maxilla usually displace the bones, therefore are easily recognized radiographically. The most useful radiographic views were dorso-ventral (Fig. 6) or ventro-dorsal and oblique lateral. Depending of the bones affected, cranium fractures were diagnosed using lateral and dorso-ventral view of the skull (Fig. 7a, b) but for a better idea regarding the affected bones, rostro-caudal view was more helpful (Fig. 12c).

#### **Dental affections and foreign bodies.**

Intraoral parallel and bisect angle technique for dental affections was used to diagnose a large area of stomatological pathology including cavities, infections, retained deciduous dentition, periodontal and endodontic disease and malocclusions. The nature of the foreign bodies found radiological was usually metallic with high density and they were radiopaque, Dorso-lateral exposure was used (Fig. 8a, b, c, d).

### **CONCLUSIONS**

The results obtained from this study show the importance of skull and dental radiography

to establish a correct diagnosis regarding the head trauma and pathology. We have managed to diagnose 3 sinus disease, 2 zygomatic fractures, 1 maxillary fracture, 2 tympanic bullae affections, 3 cranium fractures, 3 nasal bone diseases, 3 dental affections and found 4 foreign bodies. We determined the best working parameters for the TEMCO and the Poskom X-ray machines for different dog sizes and regions, the positions which require anesthesia and the best techniques for the encountered pathology (Tab. 1).

### **REFERENCES**

1. Kastner SBR (2007). BSAVA Manual of Canine and Feline Anaesthesia and Analgesia. 2<sup>nd</sup> ed., British Small Animal Veterinary Association, Gloucester, p 133.
2. Lăcătuș R, Papuc I, Muste A, Puie DS, Purdoi RC, Păvăloiu A (2010). Dental Radiographic Examination in Dogs in the Cluj Veterinary Journal 17(1):39.
3. Lisa ML (2007). Radiography in Veterinary Technology, Ed. Saunders, Missouri, pp:192-200.
4. Ruth D (2006). BSAVA Manual of Canine and Feline Musculoskeletal Imaging, British Small Animal Veterinary Association, Gloucester, p:173.
5. Thrall D (2012). Textbook of Veterinary Diagnostic Radiology, Ed. Saunders, Missouri, pp: 114-134.