

THE IMPORTANCE OF EYE FUNDUS EXAMINATION IN DIAGNOSIS OF SYSTEMIC DISEASES ON DOGS

Donisă Alina, A.Muste, L.Oana, N.Mates, F.Beteg

University of Agronomical Sciences and Veterinary Medicine, Calea Mănăştur 3-5 Cluj-Napoca
donisa_alina@yahoo.com

Key words: eye fundus, dog diabetes, retinal vessels, dog uveitis.

Abstract. This work is about the value of ophthalmoscopy in the veterinary field. We analysed eye fundus area, because he can suffer modifications not only in local diseases but in systemic diseases too. Our observations were made on dogs. We used the indirect ophthalmoscopy method with Heine OMEGA 2 C Indirect Ophthalmoscope.

INTRODUCTION

This work approaches the value and the importance of the ophthalmologic exam, in the veterinary field, with the purpose of diagnoses the diseases in this area.

Eye fundus examination (retina, choroid, optic disk), give us extremely important informations about the status health of the organism, because alongside the primary disease, the sensibility and manifestations in the fundus area are commonly with other organ diseases.

Our observations, were made on animals from canine species, who were in different pathological stages and for the examinations we used indirect ophthalmoscopy method with Heine Omega 2 C Indirect Ophthalmoscope.

MATERIAL AND METHODS

Our observations were made on ten dogs with different breeds, age and sex, brought at the Surgery Clinic from Veterinary Medicine Faculty Cluj-Napoca, between 2005-2007, to specify the diagnosis and treatment diagram. The dogs were registered by breed, age, sex and disease. (tab.1).

The studied cases between 2005-2007 (.tab1).

No. Crt.	Breed	Age	Sex	Disease
1.	<i>Golden Retriever</i>	3 years	M	Diabetes
2.	<i>Golden Retriever</i>	10 years	M	Diabetes
3.	<i>Miniature Schnauzer</i>	5 years	F	Diabetes
4.	<i>Cocker Spaniel</i>	5 years	F	Diabetes
5.	<i>Cocker Spaniel</i>	4 years	F	Diabetes
6.	<i>Rotweiler</i>	7 years	M	Diabetes
No. Crt.	Breed	Age	Sex	Disease
7.	<i>Rotweiler</i>	5 months	F	Canine distemper
8.	<i>German Shepherd</i>	6 months	M	Canine distemper
9.	<i>German Shepherd</i>	3 years	M	Skin Lymphoma
10.	<i>German Shepherd</i>	4 years	F	Skin Lymphoma

Indirect ophthalmoscopy examination, is performed after the evaluation and estimation of: general status of the organism, and we used Heine Omega 2 C Indirect Ophthalmoscope in this purpose. The patient was put in a dark room where we administered atropine 1% for pupil dilatation, simultaneously we made a contention in a very comfortable position for exam success. After that, the examiner holds the lens with thumb and forefinger and touched the animal's forehead with the remaining fingers. In that position we obtain an image of tapetal reflex. After that the examiner moved away the lens, carefully not to lose the tapetum focus, and he moved it in the same time with light until he obtain an image of the whole eye fundus. All this time he must be carefully because the light must fall perpendicularly on lens. To see the optic disk, the dog must look slightly up, the examiner head must be below the dogs head.

RESULTS AND DISCUSSIONS

For every subject, we estimate the general status of organism and clinical signs, and regarding these observations we divided that ten dogs in three groups: group one- six dogs, three male and three female, with ages between three and ten; group two- two dogs of young ages, five and six months; group three- two dogs, male and female three years old and four years old.

At clinical exam, every subject presents an characteristic or non-characteristic symptomatology for a certain disease. In that way in first group, all six specimens had clinical signs such as: weakening, who appear gradually on a period between 1-2 years, and at the moment of the examination we observed: polyuria, polydipsia, and vomiting. from group one, two specimens had clinical signs of an incipient cataract. We also made an hematological and biochemical exam at group one, and the results were glycemia value between 240mg/dl-320mg/dl.

Analyzing the clinical exam, hematological and biochemical exam results and the applied therapy, we established a diabetes diagnosis for all the specimens in this group.

In the ophthalmoscopy exam, made simultaneously with the clinical exam, we registered many modifications of the eye fundus such as: retinal folds, with different size and here and there areas with retinal detachment (fig.1). with a size of 1/3 from the entire retinal area. As localization at this specimen, the detachment area is placed at the ventral side of whole area

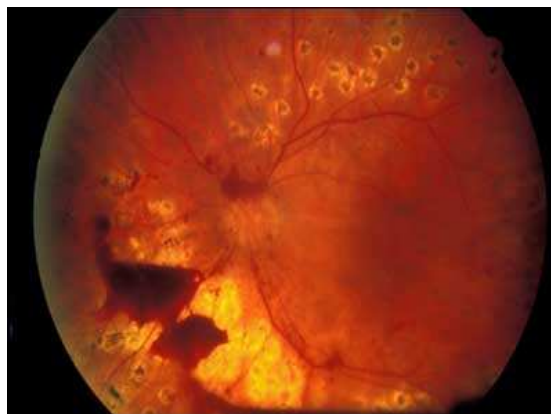

Fig.1. Retinal detachment.

In another case, at one specimen we observed a dark halo zone of fibro-hemorrhagic scar localized in the area of posterior pole.

At another specimen we observed in the eye fundus area an exudation with vessels ectasis situated upright having a cord appearance. We specify that all the modifications were localized in a single eye. This modifications are unlike with normal eye fundus (fig.2) were the tapetal reflex is well distinguished, his area is uniform, retinal vessels appear without modifications of size and volume, and retinal area is uniform, plane, velvety without folds.

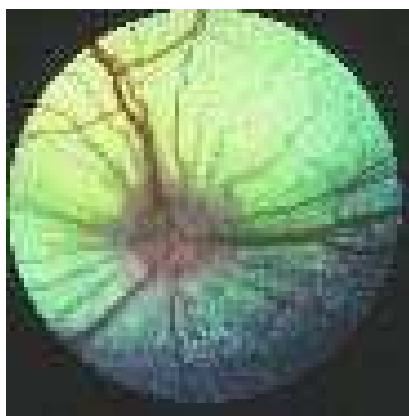


Fig.2.Normal dog eye fundus.

In other case, the specimen with the same clinical signs, bilateral eye fundus examination, showed us multifocal disseminated hemorrhages (fig.3) on the whole area and from place to place were observed little fibrous focus.

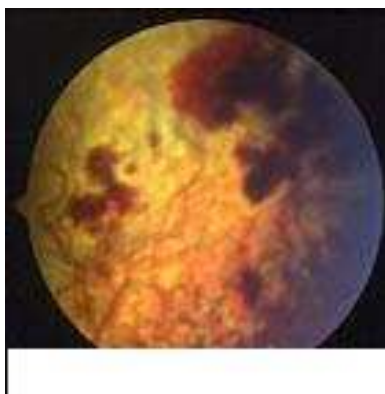


Fig.3.Retinal hemorrhage.

In the second group, clinical signs were dominated by fever, diarrhea syndrome, vomiting, deshydration, rinites, bilateral mucopurulent conjunctivitis, anorexia, the signs were observed for 3-4 days. In that two cases at the eye fundus exam, we observed passive congestion of the retinal vessels.

In the third group, symptomatology was dominated by: anorexia, progressive weakening, and diarrhea and skin nodules with general spreading tendencies, in cervical region. At one specimen we registered clinical signs of uveitis (profuse sensitiveness, congestion of conjunctivitis, exophthalmia and low vision acuteness) at both eyes.

At the eye fundus examination by indirect ophthalmoscopy method we saw retinal vessels ectasis with retinal edema(fig.4) , and at one eyeball , the retinal vessels had an anfractuous path without permeability modifications.

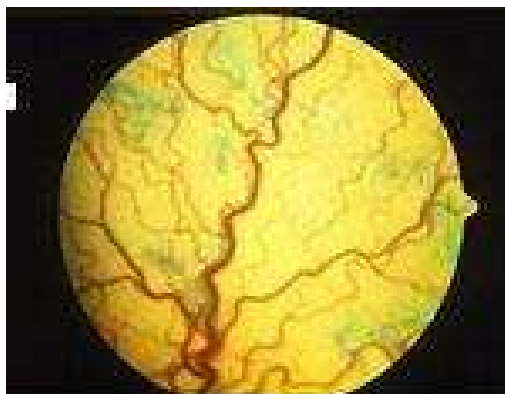


Fig.4. Retinian blood vessels ectasis

Using indirect ophthalmoscopy as approach and examination method of the eye fundus, we consider that is a very important and necessary method, because it helps us to see the modification in this area. So, in our case report, we observed that regardless of the subjects diagnoses, eye fundus was differently changed depending on the seriousness of the disease. At dogs with diabetes , because the disease advanced for a long period of time (in two cases) eye fundus had significant modifications. So, the vascularisation, the retina colour or the irregularity of retina area are extremely important elements in generally disease of the eyeball and in specially eye fundus diseases.

For one of our subjects we manage to list out particularly speaking thru indirect ophthalmoscopy, vessels modifications as ectasis and local retinal edema, even functionally speaking we didn't register any modifications. We consider this aspects as the beginning of a bigger pathological process, and find out early about this modifications contributing at the begin of therapy that can save the eyeball.

The knowledge of the eye fundus modifications has an enormous importance in ophthalmology, because the normal aspect of the fundus itself is different not only from species to species but from subject to subject in the same species.

CONCLUSIONS

1. Indirect ophthalmoscopy is a method fondness for a complete examination of eye fundus, because she allows the visualisation and shows us the details of this area.
2. Indirect ophthalmoscopy allows us to see the modifications of eye fundus that appear in some systemic disease and we can estimate the degree of illnes.
3. Indirect ophthamloscopy is preferably than direct ophthalmoscopy because avoid the animal approach, who in some cases trammel the clinical examination.
4. In our case report eye fundus have different modifications from the simple lesions (retinal vasculari ectazia) to severe lesions (retinal hemorragy, retinal detachment).
5. Even if veterinary medicine the eye fundus examinationin difficult, we consider that is necessary for a complet clinical exam of the eye.
6. The image and the accuracy of modifications of this area can't be seen without indirect ophthalmoscpy method.

BIBLIOGRAPHY

1. Appel,M.J.C.;Summers,B.A(1999).Recent advances in Canine Infectious Diseases.
2. Bojrob,M.J;Gory.W;Ellison;Barclay ,S.(1997).Current Techniques in Small Animal Surgery.(4.th edition)
3. Deneroll,P;Tessier,M;Molon-Hobolt,S.(2000).Pratique Medicale and chirurgicale de l Animal de Compagnie
4. Galatt, K.Veterinary Ophthalmology.(1994).ed. Philadelphia.
5. Krone,S.G.;Henderson,N.M.;Richardson,R.C.;Vestre,V.A.(1994).Prevalence of ocular involvement in dogs with multycentric lymphoma.
6. Laibson,P.R.(1993).Ilar Book of ophthalmology.ed Norsby.
7. Neuvians,T.P;Berger,M.(2002)Diabetes care in cats and dogs.
8. Slatter,D.(1990)Fundamentales of Veterinary Ophthalmology.ed.Philadelphia.
9. Plant,G.T.(1995).Recent advances in the electrophysiology of visual disorders.